



Determination of potential risk characteristics for cauda equina compression in emergency department patients presenting with atraumatic back pain: a 4-year retrospective cohort analysis within a tertiary referral neurosciences centre

Michelle Angus ¹, Carlos M Curtis-Lopez ², Roberto Carrasco,² Vicki Currie,¹ Irfan Siddique,³ Daniel E Horner⁴

Handling editor Loren De Freitas

► Additional supplemental material is published online only. To view, please visit the journal online (<http://dx.doi.org/10.1136/emered-2020-210540>).

¹Department of Spinal Surgery, Salford Royal NHS Foundation Trust, Salford, UK

²School of Medicine, The University of Manchester, Manchester, UK

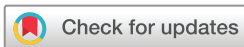³Complex Spines, Salford Royal NHS Foundation Trust, Salford, UK

⁴Emergency Department, Salford Royal NHS Foundation Trust, Salford, UK

Correspondence to

Michelle Angus, Department of Spinal Surgery, Salford Royal NHS Foundation Trust, Salford M6 8HD, UK; michelle.angus@sft.nhs.uk

Received 17 August 2020
Accepted 2 October 2021



© Author(s) (or their employer(s)) 2021. No commercial re-use. See rights and permissions. Published by BMJ.

To cite: Angus M, Curtis-Lopez CM, Carrasco R, et al. *Emerg Med J* Epub ahead of print: [please include Day Month Year]. doi:10.1136/emered-2020-210540

ABSTRACT

Objective Atraumatic back pain is an increasingly common presentation to the ED. A minority of these cases will have significant structural pathology, resulting in acute cauda equina compression (CEC). Although clinicians often look for 'red flags' to identify potential CEC, the prognostic accuracy of these presenting symptoms and clinical examination findings is unclear. We sought to evaluate the accuracy of individual clinical features in a large cohort of ED patients with atraumatic backpain and reference standard imaging, for the diagnosis of CEC.

Methods A retrospective case note review from 2014 to 2018 within an established ED atraumatic back pain pathway, undertaken at the largest tertiary spinal referral centre in the UK. We analysed routine data, collected prospectively by treating clinicians within a structured electronic health record clinical proforma. Data on signs and symptoms in 996 patients with suspected CEC referred for definitive MRI over a 4-year study period were extracted and compared against a final reference standard diagnosis.

Results We identified 111 patients with radiological evidence of CEC within the cohort referred for definitive imaging (111/996, 11.1%), of whom 109 (98.2%) underwent operative intervention. Patients with CEC were more likely to present with bilateral leg pain (OR=2.2), dermatomal sensory loss (OR 1.8) and bilateral absent ankle or ankle and knee jerks (OR=2.9). Subjective weakness was found to be associated with CEC on univariate but not multivariate analysis. We found no relationship between digital rectal examination findings and the diagnosis of CEC.

Conclusions In our cohort, factors independently associated with CEC diagnosis on MRI included bilateral leg pain, dermatomal sensory loss. Loss of lower limb reflexes was strongly suggestive of CES (likelihood ratio 3.4 on multivariate logistic regression). Our findings raise questions about the diagnostic utility of invasive digital rectal examination.

INTRODUCTION

Atraumatic back pain with or without radicular pain is a common international presentation to the EDs, accounting for between 0.9% and 17.1% of

Key messages

What is already known on this subject

- Accurate and timely diagnosis of cauda equina compression (CEC) is challenging due to variable clinical presentation, limited understanding of prognostic accuracy for clinical features and access to definitive imaging.
- Prior studies examining the prognostic accuracy of individual clinical features for the diagnosis of CEC have been limited by patient numbers and methodology. National guidelines currently highlight clinical 'red flag' diagnostic features of CEC based on expert opinion, many of which may signify late and irreversible neurological damage. There are no validated clinical decision rules to aid clinicians in identifying patients with atraumatic back pain who require urgent referral for definitive imaging.

What this study adds

- Our analysis of 4 years of prospectively collected routine clinical data for all patients with atraumatic back pain attending a tertiary ED who underwent reference standard imaging found the most frequent self-reported symptom suggestive of CEC was bilateral leg pain. The most frequent objective examination findings were dermatomal loss of sensation and bilateral absent ankle or ankle and knee jerks. We did not identify any benefit to digital rectal examination for the identification CEC.
- Our study provides guidance for which findings should have more weight in decisions to image and raises questions about the utility of an invasive rectal examination as part of this clinical examination.

all attendances.¹ A minority of these patients have cauda equina compression (CEC), with mechanical compression of the sacral nerve roots below the level of the conus medullaris. Untreated, CEC can lead to permanent neurological dysfunction, including loss of bladder control, sexual function

and sensory/motor deficit.² Due to the severity and long-term health impact of such clinical features following late diagnosis/intervention in CEC, the condition continues to have a disproportionately high medicolegal profile,³ which may lead to over investigation.

Although cauda equina syndrome is a clinical diagnosis, radiological evidence of CEC through definitive MRI is required to confirm the clinical findings and guide intervention.⁴ However, access to MRI is limited and prolongs the ED stay. The challenge for any clinician seeing patients with atraumatic back or radicular pain is to accurately identify the subgroup of patients requiring urgent imaging, to make the best use of resources and avoid overinvestigation among the much higher volume of patients attending the ED with simple musculoskeletal back pain.⁵ This challenge is compounded by rising ED attendance figures and the lack of objective, validated decision rules to guide imaging referral decisions.^{6–8}

Radiological CEC with concurrent clinical features is a surgical emergency.⁸ Studies to date have been retrospective and limited by sample size/methodology.^{9–11} A recent systematic review¹² found only seven diagnostic accuracy studies for clinical CEC (n=569 patients total); in the review, no signs or symptoms were identified that could accurately identify CEC in isolation. However, the review did not clarify which individual features had stronger discrimination. There is a clear need for further research to identify the diagnostic accuracy of individual clinical features for the diagnosis of CEC, which could help guide imaging decisions and potentially improve patient care and experience.

The aim of this study was to assess the predictive accuracy of individual signs and symptoms obtained during routine clinical assessment for the reference standard diagnosis of radiological CEC, within a large observational cohort of ED patients attending with atraumatic back pain.

METHODS

Study design

A retrospective analysis of a prospectively collected dataset at a single site major trauma, tertiary neurosciences and regional spinal referral centre.

Setting

The ED has an annual attendance of approximately 100 000. We introduced a structured assessment proforma within an established electronic patient record for atraumatic back pain at our site in January 2014, following local collaboration involving the ED, spinal surgery, radiology and allied health professional groups (online supplemental appendix 1). Key clinical variables contributing to assessment for potential CEC were agreed by services for inclusion within the proforma. All clinicians assessing patients with atraumatic back pain were encouraged (although not mandated) to use this proforma to improve the standardisation of initial assessment and decision making for this group of patients. Red flags for CEC identified by national UK guidance are highlighted within the proforma (figure 1), to provide decision support for emergency MRI referral.⁷

Patient cohort and reference standard diagnosis

All patients were clinically assessed and electronic documentation completed in real time by practising ED staff, including junior doctors, consultants and advanced nurse and physiotherapy practitioners.

Red flags symptoms and signs of cauda equina syndrome include:

- Bilateral sciatica
- Severe or progressive bilateral neurological deficit of the legs, such as major motor weakness with knee extension, ankle eversion, or foot dorsiflexion.
- Difficulty initiating micturition or impaired sensation of urinary flow, if untreated this may lead to irreversible urinary retention with overflow urinary incontinence
- Loss of sensation of rectal fullness, if untreated this may lead to irreversible faecal incontinence
- Perianal, perineal or genital sensory loss (saddle anaesthesia or paraesthesia).
- Laxity of the anal sphincter: Consider an assessment of anal tone but note that this does not need to be performed in primary care

Figure 1 National Institute for Clinical Excellence—Clinical Knowledge Summary.

Patients were included in the study if they were over 18 years and had undergone reference standard imaging (MR lumbar spine) due to a clinical suspicion of CEC. A case note review of all ED patients undergoing MR spinal imaging was conducted at the end of the study period. Patients with higher level spinal imaging (cervical or thoracic), suspected trauma, infection or malignancy were excluded from further analysis, due to the nature of the investigation.

After removing exclusions, clinical documentation was reviewed from all available records including both routine documentation and/or the structured proforma for atraumatic back pain. Data was extracted by the study team (MA and CMC-L) to include demographic data, presenting features and examination findings for all patients (including subjective and objective signs and symptoms). Missing data items were noted within the final dataset and excluded from subgroup comparisons. Single patient episodes were extracted by one reviewer only and no comparisons of inter-rater reliability were made.

All imaging reports were reviewed by the study team. Radiological compression of the cauda equina, as reported by a consultant neuroradiologist, was used as the reference standard diagnosis for CEC. This outcome was chosen above the gold standard of operative findings/adjudicated cauda equina syndrome given the study rationale, lack of comprehensive surgical intervention within our cohort and potential subjective nature of retrospective diagnosis.

Patient and public involvement

The concept of the study was developed following discussion with a patient who felt she had a poor experience in her pathway through the ED with suspected CEC. The design of the study was shared with a group of expert patients and feedback sought.

Statistical analysis

Radiological evidence of CEC was treated as a dichotomous variable. The signs and symptoms between those with and without radiological evidence of CEC were compared using χ^2 test. We considered a p value ≤ 0.05 to be statistically significant. For tests with a dichotomous outcome such as perianal sensation and anal tone, the positive and negative predictive values along with the sensitivity and specificity and likelihood ratios of the test for the reference standard diagnosis were calculated using MedCalc software.

A univariate logistic regression analysis was performed to identify the key subjective and objective risk characteristics at presentation to be associated with a diagnosis of CEC. Those statistically associated with the univariate analysis ($p \leq 0.05$) were taken forward to a multivariate analysis to evaluate independent key predictor variables. Dichotomised variables included in the final analysis were bilateral leg pain (y/n), sexual dysfunction

Table 1 Demographic data of participants and previous spinal intervention

	No radiological cauda equina compression (n=885)	Radiological cauda equina compression (n=111)
Age, years		
Range	15–93	19–91
Median (IQR)	45 (34–54)	46 (34–53)
Previous lumbar spinal surgery		
Yes	238	35
No	631	76
Initial presentation		
General practitioner	22	20
Other community clinician	10	9
ED	853	82

(y/n), bilateral weakness (y/n), sensory loss in a dermatomal distribution (y/n), bilateral reflexes absent (y/n), abnormal perianal sensation (y/n), abnormal anal tone (y/n), abnormal anal-squeeze (y/n), age ≥ 65 years (y/n) and bladder residual volume ≥ 200 mL (y/n). We report 95% CIs throughout to clarify the certainty of relevant findings.

RESULTS

During the study period, urgent inpatient MRI was requested for 2036 patients presenting to the ED with back pain to further evaluate for spinal pathology, with 996 specific requests to exclude CEC. Patient demographics are reported in [table 1](#). Radiological compression of the cauda equina was reported in 111/996 patients (11.1%) ([figure 2](#)). The vast majority of patients receiving a reference standard diagnosis of CEC went on to undergo urgent surgical decompression (109/111, 98.2%). Two patients were offered, but declined, surgical intervention.

Subjective presenting features

The subjective features reported in all patients who received reference standard imaging for suspected CEC are shown in [table 2](#), with denominators to clarify proportional recording. Bilateral leg pain and weakness were significantly more likely to be present in patients with CEC on univariate analysis, although the incidence of bilateral leg pain as a single presenting feature

was similar between groups ([table 2](#)). Unilateral pain and unilateral weakness were more likely in those without CEC. The only patient-reported symptoms that were present significantly more frequently in the CEC group were bilateral leg pain (with or without back pain) ($p < 0.001$) and the perception of weakness bilaterally ($p = 0.002$).

Patient-reported sensory symptoms including bladder sensation and dermatomal areas covered by S2-4 are reported according to reference standard diagnosis in [figure 3](#). Patients with CEC were more likely to report loss of sensation in the perianal or genital region along with the lower limb. Patients with radiological CEC also reported sexual dysfunction more frequently than those without, although this clinical symptom was infrequently documented.

Objective clinical findings

The loss of ankle jerk both unilaterally and bilaterally was more prevalent in those with CEC than those without ([table 3](#)). Dampened reflexes can occur in the older population; as such, this finding was subsequently explored further in patients under 65 years of age ([figure 4](#)). In this younger age group, no CEC patients were found to have normal reflexes. Sensory changes in the S2-4 distribution on clinical testing were more common in those patients with radiological CEC, although this was not statistically significant on univariate analysis. Anal tone was similar between the groups; anal squeeze and wink were not commonly documented as part of the clinical assessment.

Bladder imaging

Although not always performed, the use of a bladder scan to assess for a residual volume of urine after micturition was more likely to show incomplete bladder emptying in those patients with radiological CEC ([figure 5](#)).

Diagnostic test characteristics and multivariate analysis

Sensitivity, specificity and likelihood ratios for each individual objective clinical examination finding are presented by denominator in [table 4](#).

Bilateral leg pain and dermatomal sensory loss were identified as significant predictor variables ([table 5](#)), although with a modest OR. Bilateral absent reflexes appeared to be the most powerful predictor variable for the reference standard diagnosis in multivariate analysis ([table 5](#)).

DISCUSSION

In a large cohort of patients with atraumatic back pain and reference standard MRI, factors associated with radiological CEC included subjective reporting of bilateral leg pain, objective sensory loss to light touch in a dermatomal distribution and bilateral absent ankle and/or knee jerk reflexes. Bilateral weakness was associated with a positive diagnosis in univariate, but not multivariate analysis. Abnormal findings on digital rectal examination did not appear to influence the likelihood of diagnosis, in keeping with other recent studies.¹¹

In our cohort of patients presenting to the ED with atraumatic back pain who underwent urgent MRI for suspected CEC, we report a confirmation rate of 11.6% and subsequent operative intervention rate of 98.2%. The consequences of missed or delayed diagnosis of CEC can include prolonged sexual dysfunction, incontinence, weakness, immobility and sensory disturbance.⁵ These findings demonstrate the importance of robust clinical assessment and early imaging referral for features suggestive of impending CEC, which may be potentially amenable to

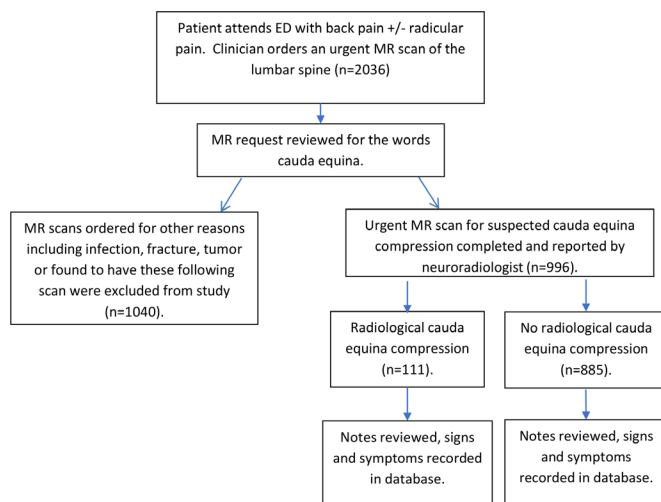
**Figure 2** Patient flowchart.

Table 2 Prevalence of the patient-reported symptoms of cauda equina syndrome per group

Variables		No cauda equina compression (n=888)	Cauda equina compression (n=117)	P value
Site of pain n=985	Back pain only	249 (29%)	19 (17%)	<0.0001*
	Unilateral leg pain±back pain	421 (48%)	49 (43%)	<0.0001*
	Bilateral leg pain±back pain	202 (23%)	45 (40%)	<0.0001*
Genital symptoms n=575	Reduced perianal sensation/saddle anaesthesia	321 (63%)	42 (63%)	0.4
	Sexual dysfunction/reduced genital sensation	66 (13%)	12 (18%)	0.4
	None	121 (24%)	13 (19%)	0.4
Bladder and bowel dysfunction n=863	Incontinence of urine	245 (32%)	25 (26%)	0.2
	Faecal incontinence±urinary symptoms	205 (27%)	22 (23%)	0.2
	Difficulty initiating urination	318 (41%)	48 (51%)	0.2
Subjective weakness n=933	Unilateral weakness	178 (22%)	16 (15%)	0.002*
	Bilateral weakness	142 (17%)	33 (31%)	0.002*
	No weakness	506 (61%)	58 (54%)	0.002*
Bladder residual n=440	≥200 mL	78 (21.4)	17 (22.7)	0.8
	<200 mL	287 (78.6)	58 (77.3)	0.8

χ^2 test was used to compare frequencies of categorical variables between radiological non-compression of the cauda equina and cauda equina compression patients.

*P value≤0.05 statistically significant.

intervention.⁹ This recent model of approach, focussing less on the ‘red flags’ of established neurological damage and more on signs of early CEC, along with others such as ‘CES suspected/early’, progressing to ‘CES incomplete’ and ‘CES with retention’^{4 13 14} suggest a linear progression of symptoms and maximise opportunity for intervention. Identification of early CEC within the context of suspected cauda equina syndrome may lead to a better prognosis post operatively.⁴

We found limited utility for bladder imaging to accurately identify early CEC, in contrast to previous work.¹⁵ This may represent increasing patient education and clinician awareness of CEC in the context of atraumatic back pain, resulting in earlier presentation and imaging referrals prior to symptoms suggestive of irreversible neurological damage (such as urinary retention). All patients within our cohort were assessed and imaged within 12 hours of their attendance to the ED. Faecal incontinence with

or without urinary symptoms did not appear to be a predictive indicator of CEC in our cohort, perhaps again due to increasing patient and clinician awareness of the diagnosis leading to earlier presentation and investigation prior to established neurological damage.^{9 16}

We found the most important patient-reported symptom of CEC to be bilateral radicular pain. This feature has been highlighted by the National Institute for Health and Care Excellence (NICE) in the UK, within their clinical knowledge summary⁷ but not in the supporting clinical guideline.¹⁷ Previous authors have suggested bilateral leg pain to be an early warning sign for CEC and that rapid diagnosis and surgical decompression at this stage may result in a good outcome for the patient.⁹ Other authors have reported unilateral radicular pain to be more prevalent than bilateral in those patients with a positive diagnosis.^{5 18} Our findings support the use of bilateral radicular pain to guide referral

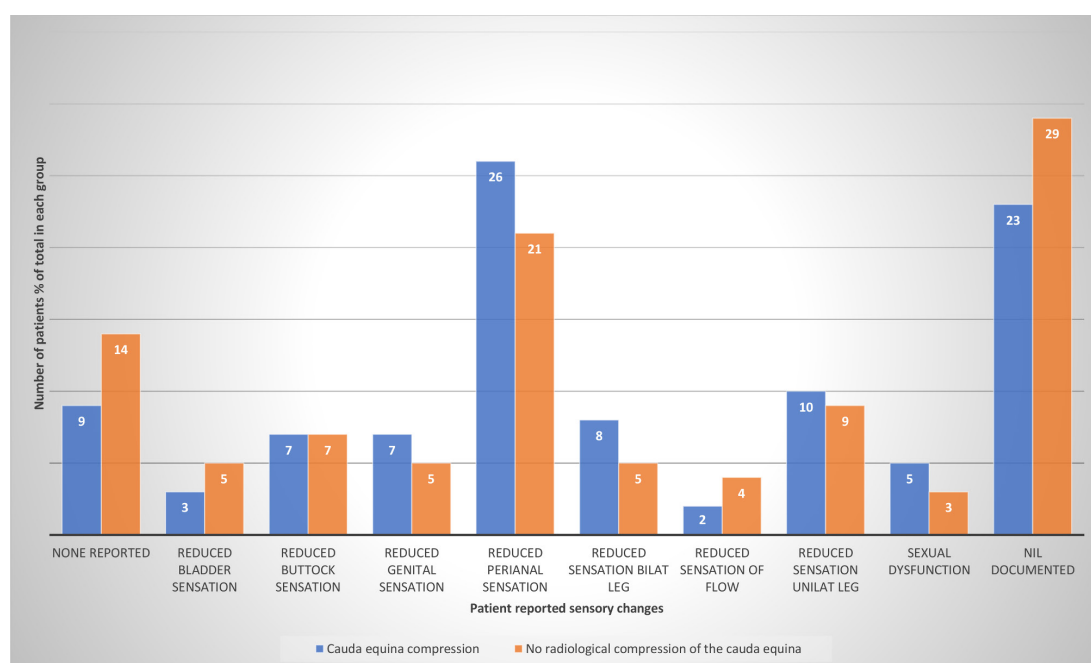


Figure 3 Patient-reported sensory changes by percentage prevalence, dichotomised to reference standard.

Table 3 Prevalence of the objective clinical findings in all patients, stratified by reference standard diagnosis

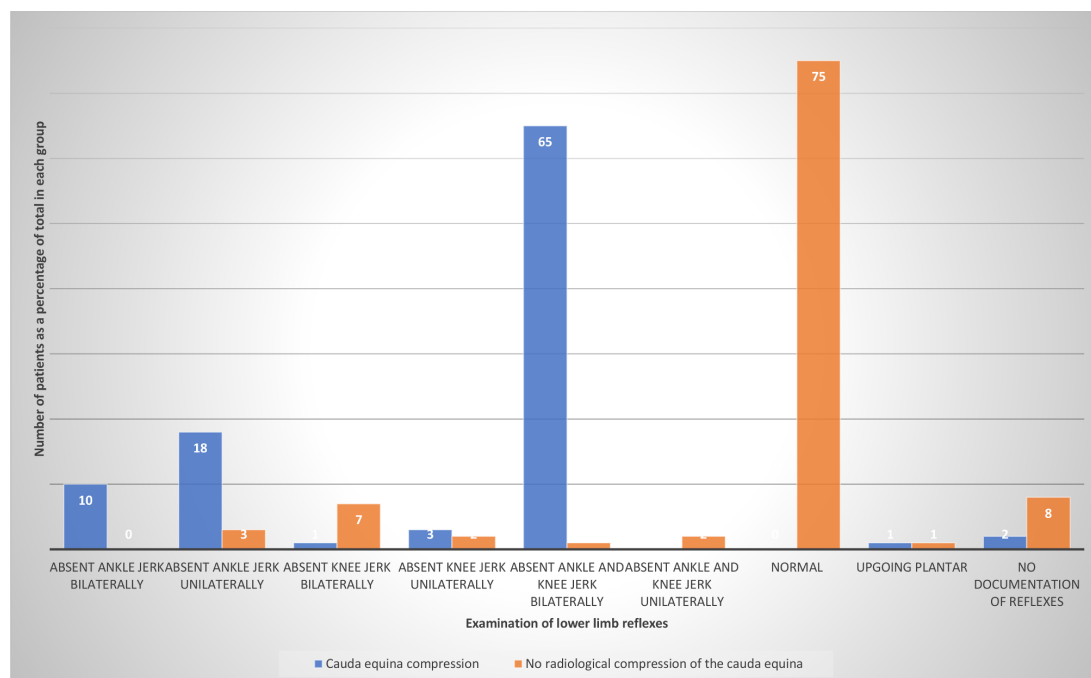
Variables		No cauda equina compression (n=888)	Cauda equina compression (n=117)	P value
Motor function n=972	Unilateral weakness	257 (30%)	37 (32%)	0.6
	Bilateral weakness	174 (20%)	26 (23%)	0.6
	No weakness	426 (50%)	52 (45%)	0.6
Sensory dysfunction n=968	Sensory loss in a dermatomal pattern	307 (36%)	57 (50%)	0.01*
	Sensory loss in a non-dermatomal pattern	168 (20%)	19 (17%)	0.01*
	No sensory loss	380 (44%)	37 (33%)	0.01*
Reflexes n=924	Absent ankle jerk bilaterally	47 (6%)	17 (15%)	0.001*
	Absent ankle jerk unilaterally	105 (13%)	21 (19%)	0.001*
	Upgoing plantar response	10 (1%)	2 (2%)	0.001*
	Normal	651 (80%)	71 (64%)	0.001*
Perianal sensation n=883	Abnormal unilaterally	145 (19%)	25 (24%)	0.4
	Abnormal bilaterally	219 (28%)	28 (27%)	0.4
	Normal	416 (53%)	50 (49%)	0.4
Anal tone n=856	Abnormal	231 (31%)	35 (35%)	0.4
	Normal	524 (69%)	66 (65%)	0.4
Anal squeeze n=309	Abnormal	84 (31%)	11 (27%)	0.6
	Normal	184 (69%)	30 (73%)	0.6

decisions for early MRI. Other patient-reported findings that were not statistically significant in this cohort include evidence of early bladder dysfunction such as difficulty initiating urination or sensation of incomplete voiding, along with self-reported sexual dysfunction. Previous work has touched on these features in isolation and the role they may have in guiding further urgent assessment; it may be helpful to promote the importance of these questions during routine clinical evaluation within an acute care setting^{19 20} as the incidence of sexual dysfunction was not routinely documented in either group.

The clinical reporting of reduced anal tone has previously been identified as a very late sign of irreversible neurological damage or lacking diagnostic accuracy, as an unreliable and subjective clinical finding.¹¹ Our study confirms these findings, suggesting

that reported abnormal anal tone is as common in those without CEC as in those with CEC. New guidelines produced for use in a primary care setting are the first to raise the limited benefits from invasive examination.²¹

Sensory loss in a dermatomal pattern (both subjective and objective) along with the loss of ankle jerks may be thought to occur with minor neural compression or irritation of the nerve root rather than the cauda equina. Our current study found these findings to be important in the early clinical consideration of CEC, perhaps due to the anatomy of a large central disc protrusion and likelihood of exiting bilateral nerve root involvement at that level. These clinical features of early CEC do not appear to have been studied in previous work.^{12 22 23}

**Figure 4** Lower limb reflexes as a per cent of total in each group.

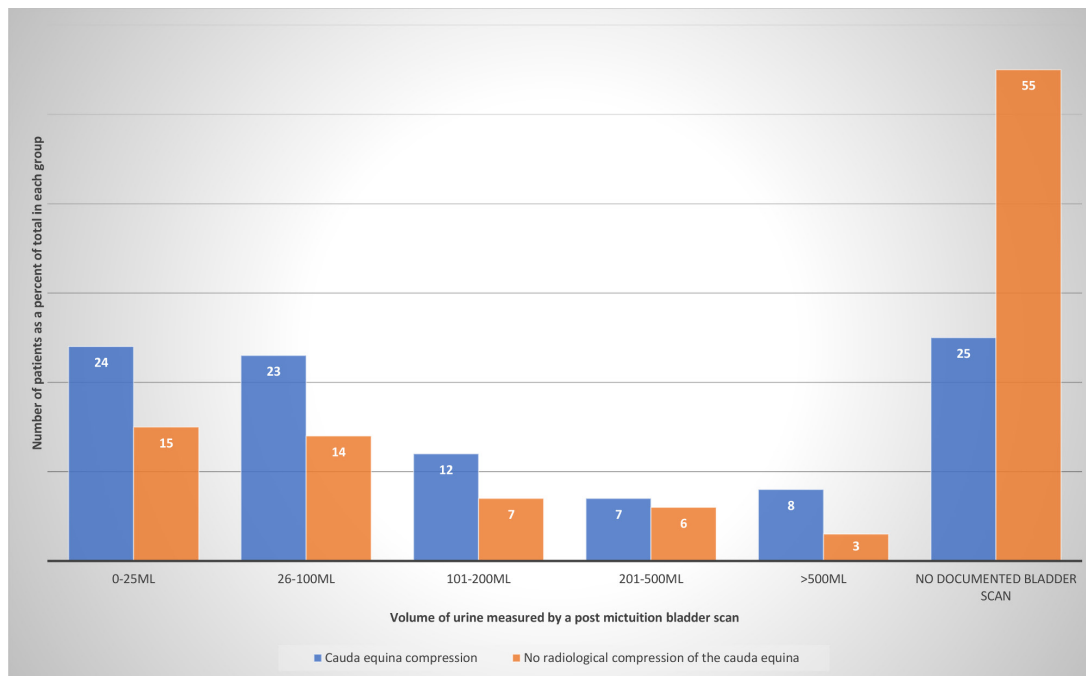


Figure 5 Volume of urine measured by a postmicturition bladder scan as a per cent of total in each group.

Our findings require external validation and confirmation in future prospective studies. However, this large cohort provides some insight into the diagnostic utility of several expert consensus reported ‘red flags’ used within the context of routine clinical assessment. Our work provides clarity around the absence of any singular examination finding that can refute the important diagnosis of CEC and highlights the limitations of invasive assessment for outdated ‘white’ flags of surrender.⁹ We also highlight the importance of previously underemphasised historical features and examination findings. Further prospective work is required across multiple sites, which could standardise a diagnostic approach and mitigate the challenges of data capture, entry and validation. Such work could validate the diagnostic accuracy of previously suggested ‘red flag’ clinical signs but also work towards development of a clinical prediction model with incorporated risk thresholds to guide imaging decisions and support shared decision making. Rather than continue to identify selected red flags in isolation and drive clinicians towards higher and higher imaging rates in order to avoid potential medicolegal pitfalls, future research should focus on risk stratification following evidence-based clinical assessment and tailored imaging recommendations. Such an approach is likely to streamline diagnostics, limit resource use and promote

timely intervention, leading to an improvement in meaningful outcomes for patients.

The strengths of this work include the large sample size of patients with reference standard diagnosis, structured real-world clinical assessment, broad statistical analysis and separation of subjective and objective clinical assessment findings. This methodology allows for a high number of positive cases to facilitate assessment of diagnostic test characteristics with a degree of precision and logistic regression analysis based on documented findings obtained within routine practice. Previous studies conducted within spinal surgery or via specialist MSK networks report prospective examination findings and ‘red flags’ found by experts^{19 24 25}; it is unclear if these previous findings are generalisable to routine assessment in secondary care.¹³

Our study has several limitations. Although we introduced a standardised proforma to facilitate data capture and promote clinical standards for care, several fields were not mandatory within this electronic document. As such, key examination findings were not recorded for every participant, as reflected in the range of denominators. This is in keeping with our previous work on the subject²⁰ and perhaps reflective of the pressures a non-spinal specialist clinician faces in a busy ED. There are no validated, generalisable or routinely used decision rules to aid

Table 4 Diagnostic test characteristics for objective clinical findings by reference standard diagnosis

Clinical finding	Sensitivity	Specificity	Negative predictive value	Positive predictive value	Positive likelihood ratio	Negative likelihood ratio
Unilateral weakness (n=772)	41.57 (31.21 to 52.51)	62.37 (58.62 to 66.02)	89.62 (87.78 to 91.22)	12.01 (9.49 to 15.10)	1.10 (0.85 to 1.44)	0.94 (0.78 to 1.13)
Bilateral weakness (n=678)	19.09 (12.22 to 27.69)	79.79 (76.94 to 82.43)	88.47 (87.45 to 89.42)	10.82 (7.48 to 15.42)	0.94 (0.63 to 1.42)	1.01 (0.92 to 1.12)
Sensory loss in a dermatomal distribution (n=931)	39.44 (28.03 to 51.75)	63.72 (60.41 to 66.94)	92.72 (91.30 to 93.93)	8.24 (6.22 to 10.82)	1.09 (0.8 to 1.47)	0.95 (0.78 to 1.15)
Absent ankle jerk bilaterally (n=771)	15.85 (8.72 to 25.58)	94.92 (93/01 to 96.44)	90.46 (89.60 to 91.25)	27.08 (17.02 to 40.22)	3.12 (1.72 to 5.65)	0.89 (0.81 to 0.98)
Absent ankle jerk unilaterally (n=802)	20.69 (12.75 to 30.71)	91.47 (89.18 to 93.41)	90.46 (89.47 to 91.36)	22.78 (15.49 to 32.21)	2.43 (1.51 to 3.90)	0.87 (0.78 to 0.97)
Abnormal perianal sensation (n=887)	50 (39.93 to 60.07)	52.99 (49.43 to 56.63)	89.56 (87.48 to 91.32)	11.62 (9.65 to 13.93)	1.06 (0.86 to 1.31)	0.94 (0.77 to 1.16)
Abnormal anal tone (n=856)	34.65 (25.46 to 44.77)	69.40 (65.98 to 72.68)	89.58 (88.09 to 90.89)	12.28 (9.49 to 15.74)	1.13 (0.85 to 1.510)	0.94 (0.81 to 1.09)
Abnormal anal squeeze (n=308)	24.39 (12.36 to 40.30)	68.16 (62.21 to 73.71)	85.45 (82.89 to 87.68)	10.53 (6.26 to 17.18)	0.77 (0.43 to 1.35)	1.11 (0.92 to 1.34)

Table 5 Univariate and multivariate logistic regression for factors associated with CEC

	Univariate logistic regression			Multivariable logistic regression (n=855)		
	OR	P value	95% CI	OR	P value	95% CI
Bilateral pain, n=985	2.2	<0.0001*	1.5 to 3.3	1.9	0.006	1.2 to 3
Bilateral weakness, n=933	2.1	0.001*	1.4 to 3.4	1.4	0.2	0.8 to 2.4
Sensory loss in a dermatomal distribution n=968	1.8	0.003*	1.2 to 2.7	1.7	0.01*	1.1 to 2.7
Bilateral ankle±knee jerk reflexes (absent), n=924	2.9	<0.0001*	1.6 to 5.3	3.4	<0.0001*	1.8 to 6.6

*P-value≤0.05 was considered statistically significant.

clinical assessment or imaging referral decisions in suspecting CEC to benchmark against. Previous attempts are limited in methodology and lack external validation.^{16 26} In addition, not all patients attending our ED with atraumatic back pain underwent definitive imaging. We have not followed up or collected data on these patients to determine clinical outcome. As such, our results refer to a selected cohort of patients, who may have a differing examination profile compared with a broader group. We also used radiological evidence of CEC compression as our reference standard and did not follow-up patients with a negative diagnosis—it remains possible that some patients without radiological compression of the cauda equina may have gone on to receive intervention or could have developed worsening symptoms requiring repeat MR with positive diagnosis at a short time point from discharge.

CONCLUSION

In this retrospective cohort study of patients attending the ED with atraumatic back pain and reference standard MRI, we found bilateral leg pain (with or without back pain), objective sensory loss (in a dermatomal distribution) and loss of bilateral ankle jerks to be predictive for a radiological diagnosis of CEC. We found limited diagnostic utility for a digital rectal examination. We suggest further prospective work to validate these findings and develop clinical prediction tools with associated risk thresholds, to guide emergency imaging decisions.

Twitter Michelle Angus @michangus

Contributors Overall guarantor: MA. Conception and design: MA and IS. Administrative support: MA and CMC-L. Provision of study materials or patients: MA, DEH, IS. Collection and assembly of data: MA, RC. Data analysis and interpretation: RC. Manuscript writing: VC, DEH, MA. Final approval of manuscript: all authors.

Funding The authors have not declared a specific grant for this research from any funding agency in the public, commercial or not-for-profit sectors.

Competing interests None declared.

Patient consent for publication Not applicable.

Ethics approval This study did not meet the formal definition of research using the HRA decision tool. The project was prospectively registered with the local research and innovation department as a service evaluation (R&D approval number S20HIP24) where the complete protocol can be obtained. Patient identifiers were not recorded in the information database and individual consent was not obtained throughout the study, as clinical care was not affected.

Provenance and peer review Not commissioned; externally peer reviewed.

Data availability statement Data are available upon reasonable request.

Supplemental material This content has been supplied by the author(s). It has not been vetted by BMJ Publishing Group Limited (BMJ) and may not have been peer-reviewed. Any opinions or recommendations discussed are solely those of the author(s) and are not endorsed by BMJ. BMJ disclaims all liability and responsibility arising from any reliance placed on the content. Where the content includes any translated material, BMJ does not warrant the accuracy and reliability of the translations (including but not limited to local regulations, clinical guidelines, terminology, drug names and drug dosages), and is not responsible for any error and/or omissions arising from translation and adaptation or otherwise.

ORCID iDs

Michelle Angus <http://orcid.org/0000-0002-7111-9290>

Carlos M Curtis-Lopez <http://orcid.org/0000-0003-0231-8867>

REFERENCES

- Edwards J, Hayden J, Asbridge M, *et al.* Prevalence of low back pain in emergency settings: a systematic review and meta-analysis. *BMC Musculoskelet Disord* 2017;18:143–55.
- Fraser S, Roberts L, Murphy E. Cauda equina syndrome: a literature review of its definition and clinical presentation. *Arch Phys Med Rehabil* 2009;90:1964–8.
- Kostusiak M, Gnanakumar S, Laing R. Incidence of cauda equina syndrome in patients transferred from district general hospitals to tertiary centre for out of hours MRI. *British Journal of Neurosurgery* 2018;32:81.
- Gleave JRW, Macfarlane R. Cauda equina syndrome: what is the relationship between timing of surgery and outcome? *Br J Neurosurg* 2002;16:325–8.
- Korse NS, Pijpers JA, van Zwet E, *et al.* Cauda equina syndrome: presentation, outcome, and predictors with focus on micturition, defecation, and sexual dysfunction. *Eur Spine J* 2017;26:894–904.
- NHS England. *Next steps on the NHS five year forward view*. London, UK, 2017.
- Sciatica (lumbar radiculopathy). *National Institute for health and care excellence clinical knowledge summary*. London UK, 2015.
- Germon T, Ahuja S, Casey ATH, *et al.* British association of spine surgeons standards of care for cauda equina syndrome. *Spine J* 2015;15:S2–4.
- Todd NV. Guidelines for cauda equina syndrome. Red flags and white flags. Systematic review and implications for triage. *Br J Neurosurg* 2017;31:336–9.
- Srikandarajah N, Clark S, Wilby M. How is timing for surgery in cauda equina syndrome defined? A systematic literature review. *Br J Neurosurg* 2018;32:81.
- Gooding BWT, Higgins MA, Calthorpe DAD. Does rectal examination have any value in the clinical diagnosis of cauda equina syndrome? *Br J Neurosurg* 2013;27:156–9.
- Hoeritzauer I, Pronin S, Carson A, *et al.* The clinical features and outcome of scan-negative and scan-positive cases in suspected cauda equina syndrome: a retrospective study of 276 patients. *J Neurol* 2018;265:2916–26.
- Todd NV, Dickson RA. Standards of care in CES. *British Journal of Neurosurgery* 2016;30:518–22.
- Sun J-C, Xu T, Chen K-F, *et al.* Assessment of cauda equina syndrome progression pattern to improve diagnosis. *Spine* 2014;39:596–602.
- Venkatesan M, Nasto L, Tsegaye M, *et al.* Bladder scans and Postvoid residual volume measurement improve diagnostic accuracy of cauda equina syndrome. *Spine* 2019;44:1303–8.
- Angus M, Berg A, Carrasco R, *et al.* The cauda scale - validation for clinical practice. *Br J Neurosurg* 2020;34:453–6.
- National Institute for Clinical Excellence. *Low back pain and sciatica in over 16s: assessment and management (NG 59)*. London, UK, 2016.
- Katzouraki G, Zubairi AJ, Hershkovich O, *et al.* A prospective study of the role of bladder scanning and post-void residual volume measurement in improving diagnostic accuracy of cauda equina syndrome. *Bone Joint J* 2020;102-B:677–82.
- Greenhalgh S, Finucane L, Mercer C, *et al.* Assessment and management of cauda equina syndrome. *Musculoskelet Sci Pract* 2018;37:69–74.
- Angus M, Horner D. Bet 2: is sexual dysfunction a recognised sign of cauda equina syndrome in the ED? *Emerg Med J* 2019;36:508–10.
- National Back Pain – Clinical Network. Early recognition of cauda equina syndrome. A framework for assessment and referral for primary care / MSK interface services, 2020. Available: <https://www.ukssb.com/nbpcn-ces-framework>
- Dionne N, Adefolarin A, Kunzelman D, *et al.* What is the diagnostic accuracy of red flags related to cauda equina syndrome (CEs), when compared to magnetic resonance imaging (MRI)? A systematic review. *Musculoskelet Sci Pract* 2019;42:125–33.
- McDonnell J, Ahern DP, Gibbons D, *et al.* A systematic review of the presentation of scan-negative suspected cauda equina syndrome. *Surgeon* 2020;18:49–52.
- Cook CE, George SZ, Reiman MP. Red flag screening for low back pain: nothing to see here, move along: a narrative review. *Br J Sports Med* 2018;52:493–6.
- Finucane LM, Downie A, Mercer C, *et al.* International framework for red flags for potential serious spinal pathologies. *J Orthop Sports Phys Ther* 2020;50:350–72.
- Todd NV. Quantifying the clinical aspects of the cauda equina syndrome - The Cauda Scale (TCS). *Br J Neurosurg* 2018;32:260–3.